

Reduced Brain White Matter Integrity in Trichotillomania

A Diffusion Tensor Imaging Study

Samuel R. Chamberlain, MD, PhD; Adam Hampshire, PhD; Lara A. Menzies, MD, PhD; Eleftherios Garyfallidis, MSc; Jon E. Grant, MD, MPH; Brian L. Odlaug, BA; Kevin Craig, MD; Naomi Fineberg, MD; Barbara J. Sahakian, PhD

Context: Trichotillomania is an Axis I disorder characterized by repetitive, pathological hair pulling.

Objective: To assess the integrity of white matter tracts in subjects with the disorder.

Design: Between-group comparison using permutation cluster analysis, with stringent correction for multiple comparisons.

Setting: Academic psychiatry department.

Participants: Eighteen volunteers meeting *DSM-IV* criteria for trichotillomania and 19 healthy control subjects.

Main Outcome Measures: Fractional anisotropy (measured using diffusion tensor imaging), trichotillomania

disease severity (Massachusetts General Hospital Hair-pulling Scale score), and dysphoria (Montgomery-Asberg Depression Rating Scale score).

Results: Subjects with trichotillomania exhibited significantly reduced fractional anisotropy in anterior cingulate, presupplementary motor area, and temporal cortices. Fractional anisotropy did not correlate significantly with trichotillomania disease severity or depressive mood scores.

Conclusions: These data implicate disorganization of white matter tracts involved in motor habit generation and suppression, along with affective regulation, in the pathophysiology of trichotillomania.

Arch Gen Psychiatry. 2010;67(9):965-971

Author Affiliations:

Department of Psychiatry and Medical Research Council Wellcome Trust Behavioural and Clinical Neurosciences Institute (Drs Chamberlain, Menzies, Craig, Fineberg, and Sahakian) and Medical Research Council Cognition and Brain Sciences Unit (Dr Hampshire and Mr Garyfallidis), University of Cambridge, Cambridge, England; and Department of Psychiatry, University of Minnesota Medical Center, Minneapolis (Dr Grant and Mr Odlaug).

TRICHOTILLOMANIA IS A NEUROPSYCHIATRIC disorder characterized by the repetitive pulling out of one's own hair, leading to noticeable hair loss and significant functional impairment.¹ Although the phenomenon of hair pulling has been recognized for centuries, appearing in works attributed to Hippocrates and described more recently by the French dermatologist Hallopeau,² it has only recently been subjected to psychiatric scrutiny.³ Indeed, one of the first case series to explore pathological hair pulling was published in the *Archives of General Psychiatry* in the 1960s.⁴ Since then, trichotillomania has been included in the *DSM-IV* as an impulse control disorder, alongside pyromania, kleptomania, and pathological gambling.¹

Relatively little is known of the epidemiology and phenomenology of trichotillomania. Based on a college student sample, lifetime prevalence was estimated to be 0.5% to 2% depending on how strictly *DSM-IV* criteria were applied.⁵ An-

other study reported that 3.9% of students in a college sample met *DSM-IV* criteria for trichotillomania.⁶ According to the current *DSM-IV* criteria, hair pulling is associated with growing tension beforehand and relief, gratification, or pleasure afterward. Survey data suggest that trichotillomania is associated with impediments in forming (and maintaining) social relationships, family life, work productivity, and sports.^{7,8} Trichotillomania typically begins in adolescence and is thought to be more preponderant in women, since the overwhelming majority of clinical trial recruits have been female.⁹ Individuals with trichotillomania may pluck hair from any body site, but they most frequently pluck from the scalp, eyebrows, and/or eyelashes. Trichotillomania can be viewed as a pathological grooming behavior alongside pathological nail biting and skin picking.¹⁰

The nosological status of trichotillomania and its relationship to other Axis I disorders remain in dispute. People with trichotillomania show unexpectedly high

rates of obsessive-compulsive disorder (OCD) and vice versa,^{11,12} and first-degree relatives of patients with OCD show unexpectedly high rates of grooming behaviors including trichotillomania.¹³ Given this overlapping familiarity and that both conditions are associated with pathological habits that are difficult to suppress, it has been suggested that trichotillomania represents a member of the putative obsessive-compulsive spectrum.¹⁴⁻¹⁷ Also, trichotillomania bears phenomenological similarities with Tourette syndrome in that hair pulling and tics are both often stereotyped, are commonly preceded by an urge to undertake the behavior, and are followed by a sense of relief.¹⁸

Various imaging techniques and neurocognitive approaches have proven fruitful in the context of OCD, leading to the generation of a neurobiological model of the disorder emphasizing abnormalities in the orbitofrontal cortices (OFCs), posterior parietal cortices, and caudate.¹⁹ There have been very few such applications to trichotillomania to compare brain structure in those with trichotillomania with that of healthy control subjects. Most structural imaging studies of trichotillomania to date have used region-of-interest approaches and, by virtue of the analysis techniques used and sample sizes, have not had sufficient power for results to withstand multiple comparisons. Early research found that trichotillomania was associated with reduced putamen volumes²⁰ (as has also been reported for Tourette syndrome²¹), although another trichotillomania study was negative in this regard.²² Other imaging studies of trichotillomania reported reduced gray matter in the left inferior frontal gyrus²³ and reduced cerebellar volumes.²⁴ More recently, whole-brain analysis identified increased gray matter densities in the left caudate/putamen, bilateral cingulate, and right frontal cortices.²⁵

Although these studies implicate structural abnormalities within particular gray matter regions, it is not known whether trichotillomania is also associated with aberrant connectivity of white matter tracts between these particular nodes of frontostriatal circuitry. Information regarding dysconnectivity of white matter tracts would be important from several perspectives in addition to informing the nosological issues described earlier. The symptoms of trichotillomania are particularly suited to translational modeling, being overt and relatively simple—as opposed, for example, to intrusive thoughts in OCD and often complex compulsions therein.²⁵ Translational approaches to the study of hair pulling and aberrant grooming have yielded several promising animal models argued to capture aspects not only of trichotillomania but also of obsessive-compulsive spectrum disorders more broadly.^{26,27} Furthermore, pharmacological treatment studies of trichotillomania have been disappointing, and improved understanding of the neurobiology could inform novel treatment directions.²⁸ Lastly, based on familial data and the only twin study of its kind to date, it is likely that genetic influences are considerable in the disorder.²⁹ Brain-based markers are ideally placed to serve as candidate endophenotypes to help elucidate these as-yet-unknown genetic mediators of risk.³⁰

Diffusion tensor imaging (DTI) is a magnetic resonance imaging (MRI) technique that allows for the in-

direct assessment of the integrity of white matter tracts³¹ by means of measurement of the extent and direction of water diffusion within the brain. When unconstrained, water molecules diffuse randomly in all directions and thus exhibit isotropy. Within white matter tracts, the movement of water molecules is physically constrained along the direction of tracts by sheaths of myelin, a phenomenon referred to as anisotropy, which is represented as an ellipsoid in tensor form.^{32,33} Reduced fractional anisotropy (FA), indicating more isotropic diffusion, is characteristic of damaged and/or disorganized white matter tracts.³⁴

The aim of this study was to assess the integrity of white matter tracts in subjects with trichotillomania compared with healthy control subjects. In particular, we sought to conduct an analysis across all white matter tracts within the brain using DTI alongside recently validated and statistically powerful methods of permutation cluster analysis to ensure stringent corrections for multiple comparisons.³⁵⁻³⁸ Substantive tiers of research support the view that the generation and top-down suppression of motoric habits are mediated by distributed circuitry including the right frontal cortex, bilateral anterior cingulate cortices, and motor/motor association cortices.^{39,40} Aberrant structure and function of these regions have been implicated in the pathophysiology of both trichotillomania⁴¹ and tics.⁴² It was hypothesized that trichotillomania would be associated with disorganized white matter tracts, ie, reduced FA, within the white matter tracts connecting these regions.

METHODS

Subjects with trichotillomania were recruited via advertisements on support Web sites and healthy volunteers were recruited via media advertisements in the United Kingdom. Interested persons contacted the study team and were asked to complete a medical questionnaire, which was returned via post or e-mail. The questionnaire inquired about past and current diagnosis of psychiatric disorders, any medications and psychotherapy received, possible contraindications to MRI, and demographic details (a copy is available from us on request). Questionnaires were screened by a member of the study team; when inclusion criteria (listed later) were provisionally met, this was confirmed by inviting subjects to attend a clinical interview. Eight potential trichotillomania recruits were excluded from participation prior to interview (4 for presence of and/or receiving treatment for depression; 2 for contraindications to MRI; and 2 for not fulfilling DSM-IV criteria for trichotillomania).

The interview included the Mini International Neuropsychiatric Inventory,⁴³ a well-validated screening tool for Axis I disorders. The Mini International Neuropsychiatric Inventory was supplemented with additional questions relating to DSM-IV criteria for the impulse control disorders (including trichotillomania) and history of diagnosed Axis I conditions. The interview also included assessment of verbal IQ (using the National Adult Reading Test)⁴⁴ and levels of depressive mood (Montgomery-Asberg Depression Rating Scale [MADRS]).⁴⁵ Disease severity in subjects with trichotillomania was quantified using the Massachusetts General Hospital (MGH) Hairpulling Scale.^{46,47}

Trichotillomania cases were enrolled on the basis of meeting DSM-IV criteria for the disorder, being free from clinically

significant levels of depression (not fulfilling DSM-IV criteria for major depressive disorder and having MADRS scores <10), and being free from psychological and psychopharmacological treatment for at least 6 months. Trichotillomania inclusion criteria also required absence of comorbid OCD, pyromania, kleptomania, and pathological gambling. Control subjects were recruited on the basis of freedom from Axis I disorders according to the Mini International Neuropsychiatric Inventory and absence of clinically significant levels of depression (not fulfilling DSM-IV criteria for major depressive disorder and having MADRS scores <10). Exclusion criteria across all participants were history of serious head injury, history of substance abuse, history of neurologic disorders (including epilepsy and tics), contraindication to MRI, and National Adult Reading Test IQ less than 90. Additionally, subjects with significant macroscopic structural brain abnormalities on MRI (eg, lesions, masses, evidence of cerebrovascular events) according to a consultant radiologist independent of the research group were excluded. Conventional MRI data from this sample were reported previously.²⁵

NEUROIMAGING

The MRI scans were acquired using a 1.5-T GE Signa system (GE Healthcare, Milwaukee, Wisconsin) at the Department of Radiology, Addenbrooke's Hospital, Cambridge, England. Diffusion-weighted imaging data were acquired (25 directions) with slice thickness of 4 mm, temporal resolution of 12 seconds, echo time of 93 milliseconds, matrix size of 128 × 128, field of view of 30 × 24 cm, and B value of 1000 s/mm². One volume without diffusion weighting (b=0) was also acquired. To provide a reference for normalization, axial 3-dimensional T1-weighted images were obtained using a spoiled gradient recall sequence with slice thickness of 2 mm, temporal resolution of 33 milliseconds, echo time of 3 milliseconds, field of view of 24 cm, flip angle of 40°, and matrix size of 256 × 256.

STATISTICAL ANALYSES

Potential differences in demographic characteristics between the 2 study groups were investigated using independent sample *t* tests, with significance defined as *P* < .05 uncorrected. Methods of imaging preprocessing and analysis have been validated previously and are described in depth in our previous DTI OCD study.³⁶ First, brain tissue was extracted using the Brain Extraction Tool in FSL software (FMRIB Centre, Department of Clinical Neurology, University of Oxford, Oxford, England; <http://www.fmrib.ox.ac.uk/fsl/>).⁴⁸ Brain maps for each of the 25 directions were eddy corrected subsequent to which FA values were calculated at each voxel using the FSL FMRIB Diffusion Toolbox. The b=0 images were coregistered with the structural T1-weighted image for each person, the same coregistration parameters were applied to the FA maps, each individual's T1-weighted image was normalized to the statistical parametric mapping T1 template (in Montreal Neurological Institute [MNI] standard space), and the same normalization parameters were then applied to the coregistered FA images. Thus, each individual's FA maps were converted into MNI space using SPM5 software (Wellcome Department of Imaging Neuroscience, London, England). Next, the FA images were smoothed with an 8-mm full-width at half-maximum Gaussian kernel, and a white matter mask was used to restrict the search volume for analysis to mitigate multiple comparisons. The white matter mask was created by binarizing the statistical parametric mapping a priori white matter template to a binary mask, ie, thresholding each voxel at 50% white matter to define white matter regions for analysis.

An analysis of covariance model was then fitted at each intracerebral voxel in standard space using those images generated via the procedures described earlier. The null hypothesis of there being no significant difference in FA between the 2 groups was tested using permutation analysis at the level of spatially contiguous 3-dimensional voxels, implemented in Cambridge Brain Activation software version 2.3.0 (Brain Mapping Unit, Department of Psychiatry, University of Cambridge, Cambridge, England; <http://www-bmu.psychiatry.cam.ac.uk/>) and described in detail elsewhere.^{35,38} We used tight statistical correction such that the number of expected false-positive identified clusters across the whole analysis was less than 1. Clusters showing significant between-group differences were described in terms of (1) their peak coordinates in MNI space and (2) the brain areas (Brodmann areas [BAs]) contained therein. Mean FA values for each subject for each identified cluster were extracted and presented in graphical form. To investigate possible relationships between white matter abnormalities in trichotillomania and disease severity, correlational analyses (Spearman ρ) were undertaken between mean FA and MGH Hairpulling Scale total scores across the trichotillomania cases. To assess possible relationships between white matter integrity and subclinical dysphoria within each group, similar correlational analyses were undertaken between mean FA and MADRS total scores.

RESULTS

Twenty subjects with trichotillomania and 19 control subjects met provisional inclusion criteria and attended the medical interview. None were excluded at the interview stage. Clinically significant structural abnormalities were identified in 2 subjects with trichotillomania, whose data were excluded from the subsequent analyses. One subject had a signal hyperintensity of uncertain clinical significance in the basal ganglia; the other exhibited evidence of a previous brainstem event (ie, stroke) and was urgently referred to her medical practitioner.

Demographic characteristics of the included sample are shown in the **Table**, where it can be seen that the groups did not differ significantly in terms of age, IQ, sex, or handedness. The trichotillomania group showed mild to moderate hair-pulling disease severity (MGH Hairpulling Scale scores) and significantly higher levels of depressive mood (MADRS scores) than healthy control subjects, as expected. One subject with trichotillomania met criteria for current panic disorder and agoraphobia, but the others were free from Axis I comorbidities as indexed by the screening interview.

Permutation analysis identified 3 clusters of brain regions in which there were significant FA differences between the 2 study groups (**Figure**). The group with trichotillomania as compared with control subjects showed abnormally reduced FA in distributed white matter tracts connecting the bilateral anterior cingulate cortices (BAs 24 and 32), the bilateral OFC (BA 11), the pre-supplementary motor area (pre-SMA) (BA 6), the left primary somatosensory cortex (BA 2), and multiple temporal regions (BAs 20 and 44). Cluster 1 had peak MNI coordinates of [-34, -42, 14] and a size of 1840 voxels and included mainly left superior and middle temporal regions. Cluster 2 had peak coordinates of [20, 26, 26] and a size of 553 voxels and comprised the bilateral an-

Table. Descriptive Characteristics of Subjects With Trichotillomania and Healthy Control Subjects

Characteristic	Trichotillomania	Control	F Score	P Value
Age, mean (SD), y	37.39 (11.65)	33.05 (9.09)	1.61	.21
Verbal IQ, mean (SD)	115.52 (7.11)	111.73 (9.20)	1.95	.17
Sex, No.			1.00	.32 ^a
Male	1	3		
Female	17	16		
Handedness, No.			0.30	.59 ^a
Left	3	2		
Right	15	17		
MADRS score, mean (SD)	3.17 (4.71)	0.21 (0.63)	7.37	.01
MGH Hairpulling Scale total score, mean (SD)	15.11 (4.54)
Age at symptom onset, mean (SD), y	11.89 (6.85)

Abbreviations: MADRS, Montgomery-Asberg Depression Rating Scale; MGH, Massachusetts General Hospital; ellipsis, not applicable.

^aFrom χ^2 test.

terior cingulate cortices and OFC. Cluster 3 had peak coordinates of $[-28, -18, 54]$ and a size of 138 voxels and comprised mainly the left pre-SMA. There was no evidence for significant correlations between FA and trichotillomania disease severity, nor between FA and MADRS scores (all $P > .20$).

COMMENT

Although the concept of pulling out one's hair is ingrained in the popular mindset, the neurobiology of pathological hair pulling as manifested in trichotillomania has received scant research attention. To our knowledge, this is the first study to explore the integrity of white matter tracts in volunteers with the disorder. The key finding was that trichotillomania was associated with reduced integrity of white matter tracts connecting the bilateral OFC and anterior cingulate cortices, the left pre-SMA, and the left temporal lobe (Figure). These abnormalities occurred in the absence of confounding effects of treatment (medications and psychotherapy) in a sample largely free from comorbid Axis I disorders. Previous structural imaging studies conducted in trichotillomania provided mixed evidence to support the existence of gray matter abnormalities in the putamen, anterior cingulate cortices, cerebellum, and frontal cortices.^{20,23,24} The current data expand significantly on this prior work by implicating dysconnectivity in white matter tracts connecting neural regions involved in motor generation and suppression as well as emotional processing in the pathophysiology.

Trichotillomania is characterized by a repetitive, often somewhat stereotyped motoric habit that is difficult to suppress, and we previously reported impairment on the well-validated stop-signal test of motor inhibition in subjects with the disorder.⁴⁹ Most white matter tracts found to be abnormal in trichotillomania herein are closely affiliated with gray regions mediating the generation and suppression of motor habits. The pre-SMA has classically been associated, across species, with the preparation and selection of movements and with high-level functions relating to motor preparation.³⁹ Indeed, the pre-SMA is richly connected with prefrontal and other nonprimary motor cortical areas, which are involved in

cognition.^{50,51} Multiple tiers of imaging evidence in humans suggest that the OFC and anterior cingulate cortices play cardinal roles in response suppression, working alongside other neural regions such as the right inferior frontal gyrus and the pre-SMA to act as a break over ongoing behavior.^{42,52-57}

We also identified white matter abnormalities within the temporal cortex, which is important in aspects of mnemonic processing and emotional regulation. There is evidence for spatial working memory deficits in people with trichotillomania.^{58,59} The temporal lobes, especially BA 20, have been implicated in the processing of negative emotions.⁶⁰ Emotional dysregulation is central to trichotillomania in that hair pulling is often associated with initial tension and subsequent relief. It has been proposed that hair pulling acts to moderate high-arousal (anxiety) and low-arousal (boredom) states.⁶¹ Situations of emotional significance often act as hair-pulling triggers,⁶² and emotional factors appear to play a causal role in the etiology.⁶²⁻⁶⁴ Furthermore, the anterior cingulate, notably BA 24, is strongly implicated in the manifestation of mood disorders⁶⁵ and represents the primary site for deep brain stimulation in treatment-resistant depressive cases.⁶⁶

We did not find any significant correlations between brain FA and past-week MGH Hairpulling Scale disease severity, nor between FA and MADRS depressive mood scores. Thus, the extent of DTI abnormalities did not bear an overt relationship with current (past week) clinical disease severity. The lack of significant correlation could be owing to the relatively narrow range of MGH Hairpulling Scale and MADRS scores because subjects had mild to moderate disease severity and were free from clinically significant depression. It may also be the case that these white matter abnormalities represent a candidate intermediate marker of disease vulnerability (ie, candidate endophenotype) that predisposes to repetitive habits but does not bear a direct relationship with severity of disease.⁶⁷ For example, in OCD, white matter tract abnormalities on DTI did not correlate with disease severity in patients and were also found in unaffected first-degree relatives of patients in the absence of clinical symptoms.³⁶

It is potentially informative to compare these findings in trichotillomania with prior DTI studies con-

ducted in related disorders, including *DSM-IV* impulse control disorders, OCD, and Tourette syndrome. There have been virtually no DTI studies in other impulse control disorders. Grant et al⁶⁸ found evidence for reduced white matter integrity in frontal tracts in subjects with kleptomania but did not explore local abnormalities. Several studies have found decreased FA in cingulate regions in patients with OCD,^{69,70} but not consistently.³⁶ Two DTI studies have been performed in Tourette syndrome. The first study reported reduced corpus callosum connectivity in children with the disorder,⁷¹ while the second, using whole-brain morphometry in adults, reported bilateral FA increases in white matter underlying the postcentral and precentral gyri, below the left supplementary motor area, and in the right ventroposterolateral part of the thalamus.⁷² Viewed collectively, these findings implicate white matter abnormalities across these related Axis I disorders but suggest that the neurobiology differs somewhat between them.

Two recruits with trichotillomania were excluded from the current analysis owing to macroscopic structural brain abnormalities detected during clinical screening. One subject had a white matter signal hyperintensity in the basal ganglia, while the other had likely had a brainstem stroke. Although our study cannot assess causation between these brain abnormalities and the occurrence of trichotillomania, it is interesting to note that the proportion of trichotillomania cases exhibiting such abnormalities (approximately 10%) is greater than would have been expected by chance alone.

This study has several positive features, notably that it is the first to use DTI in trichotillomania, that it uses permutation cluster analysis, and that subjects with trichotillomania were free from treatment for at least 6 months prior to participation and for the most part were free from Axis I comorbidities. However, several limitations should be considered. Because we recruited from Web/media advertisements, there is the possibility of selection bias. We do not yet know whether these findings in moderately ill people recruited via advertisements and having few comorbidities generalize to trichotillomania more broadly. The imaging methods themselves have limitations such as potential white matter tract misalignment and the use of smoothing kernels.³⁶ The ability to detect any significant correlational relationships between structural abnormalities and disease severity was likely constrained by the narrow range of scores exhibited and by the fact that we did not collect lifetime (only past week) severity scores. Finally, we did not have access to subjects' medical records; therefore, our strategy to elicit current Axis I disorders and history of Axis I disorders was based on self-completed questionnaire and subsequent clinical interview, which may have hindered the reliability to detect comorbidities in the past and present.

In addition to resolving these issues, future work should also examine the neurobiological overlap between trichotillomania, other impulse control disorders, Tourette syndrome, and OCD. Diffusion tensor imaging could be used in conjunction with functional imaging (eg, functional MRI) to explore the relationship between white matter tract disorganization and dysfunction of particular nodes within the networks respon-

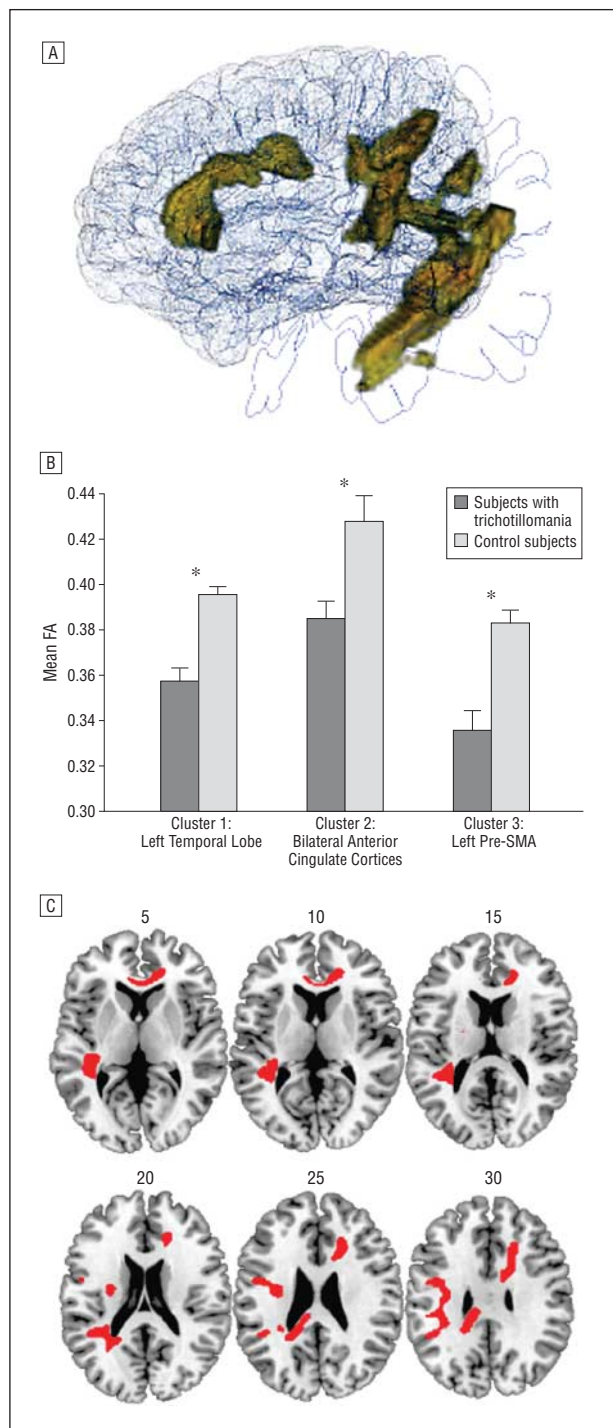


Figure. Regions exhibiting reduced white matter tract integrity (fractional anisotropy [FA]) in subjects with trichotillomania compared with healthy control subjects. A, Three-dimensional rendering of clusters with abnormally low FA, created using Fos 3D engine for brain imaging (Medical Research Council Cognition and Brain Sciences Unit, Cambridge, England). B, Mean FA in each group for each of the 3 brain clusters. Arbitrary units are used. Error bars indicate SEM; pre-SMA, presupplementary motor area. *Significant difference between groups ($P < .001$). C, Transverse brain slices with regions of reduced FA shown in red (numbers indicate z coordinates in Montreal Neurological Institute space).

sible for habit suppression and affective regulation. Studies should statistically compare abnormalities identified between groups of subjects with these purportedly related clinical conditions.

Submitted for Publication: December 7, 2009; final revision received March 5, 2010; accepted April 26, 2010.
Correspondence: Samuel R. Chamberlain, MD, PhD, Department of Psychiatry, University of Cambridge, Box 189, Addenbrooke's Hospital, Cambridge, CB2 0QQ, England (srchamb@gmail.com).

Author Contributions: Drs Chamberlain and Hampshire contributed equally to this work.

Financial Disclosure: Dr Chamberlain consults for Cambridge Cognition, Shire, and P1Vital. Dr Menzies has received financial compensation resulting from the transfer of a technology not relating to the subject matter of this article between Cambridge Enterprise Ltd, University of Cambridge, and a biotechnology company; has received an honorarium for speaking at the Eighth Annual Meeting of Research on Psychopathology (2007); and has had her work supported by the Harnett Fund (University of Cambridge; MB/PhD studentship). Dr Grant has received research grants from Forest Pharmaceuticals and GlaxoSmithKline and has been a consultant to Somaxon Pharmaceuticals and for law offices as an expert in pathological gambling. Dr Craig is employed by P1Vital. Dr Fineberg has been a consultant to Lundbeck, GlaxoSmithKline, Servier, and Bristol-Myers Squibb; has received research support from Lundbeck, GlaxoSmithKline, AstraZeneca, the Wellcome Trust, and the European College of Neuropsychopharmacology; has received honoraria for lecturing at scientific meetings from Janssen, Jazz, Lundbeck, Servier, AstraZeneca, and Wyeth; and has received financial support to attend scientific meetings from Janssen, Bristol-Myers Squibb, Jazz, Lundbeck, Servier, AstraZeneca, Wyeth, Cephalon, and the International College of Obsessive Compulsive Spectrum Disorders. Dr Sahakian has been a consultant to Cambridge Cognition and is supported by a Wellcome Trust Programme Grant.

Funding/Support: This work was supported by the Behavioural and Clinical Neuroscience Institute, which is supported jointly by the Medical Research Council and Wellcome Trust.

REFERENCES

1. American Psychiatric Association. *Diagnostic and Statistical Manual of Mental Disorders*. 4th ed. Washington, DC: American Psychiatric Association; 1994.
2. Hallopeau H. Sur un nouveau cas de trichotillomanie. *Ann Dermatol Syphiligr (Paris)*. 1894;5:541-543.
3. Chamberlain SR, Odlaug BL, Boulougouris V, Fineberg NA, Grant JE. Trichotillomania: neurobiology and treatment. *Neurosci Biobehav Rev*. 2009;33(6):831-842.
4. Greenberg HR, Sarner CA. Trichotillomania: symptom and syndrome. *Arch Gen Psychiatry*. 1965;12:482-489.
5. Christenson GA, Pyle RL, Mitchell JE. Estimated lifetime prevalence of trichotillomania in college students. *J Clin Psychiatry*. 1991;52(10):415-417.
6. Odlaug BL, Grant JE. Impulse control disorders in a college sample. *Prim Care Companion J Clin Psychiatry*. In press.
7. Woods DW, Flessner CA, Franklin ME, Keuthen NJ, Goodwin RD, Stein DJ, Walther MR; Trichotillomania Learning Center—Scientific Advisory Board. The Trichotillomania Impact Project (TIP): exploring phenomenology, functional impairment, and treatment utilization. *J Clin Psychiatry*. 2006;67(12):1877-1888.
8. Diefenbach GJ, Tolin DF, Hannan S, Crocetto J, Worhunsky P. Trichotillomania: impact on psychosocial functioning and quality of life. *Behav Res Ther*. 2005;43(7):869-884.
9. Chamberlain SR, Menzies L, Sahakian BJ, Fineberg NA. Lifting the veil on trichotillomania. *Am J Psychiatry*. 2007;164(4):568-574.
10. Odlaug BL, Grant JE. Trichotillomania and pathologic skin picking: clinical comparison with an examination of comorbidity. *Ann Clin Psychiatry*. 2008;20(2):57-63.
11. Fontenelle LF, Mendlowicz MV, Versiani M. Impulse control disorders in patients with obsessive-compulsive disorder. *Psychiatry Clin Neurosci*. 2005;59(1):30-37.
12. Richter MA, Summerfeldt LJ, Antony MM, Swinson RP. Obsessive-compulsive spectrum conditions in obsessive-compulsive disorder and other anxiety disorders. *Depress Anxiety*. 2003;18(3):118-127.
13. Lenane MC, Swedo SE, Rapoport JL, Leonard H, Sceery W, Guroff JJ. Rates of obsessive compulsive disorder in first degree relatives of patients with trichotillomania: a research note. *J Child Psychol Psychiatry*. 1992;33(5):925-933.
14. Kuzma JM, Black DW. Compulsive disorders. *Curr Psychiatry Rep*. 2004;6(1):58-65.
15. Hollander E, Rosen J. Impulsivity. *J Psychopharmacol*. 2000;14(2)(suppl 1):S39-S44.
16. Stein DJ, Simeon D, Cohen LJ, Hollander E. Trichotillomania and obsessive-compulsive disorder. *J Clin Psychiatry*. 1995;56(suppl 4):28-35.
17. Swedo SE, Leonard HL. Trichotillomania: an obsessive compulsive spectrum disorder? *Psychiatr Clin North Am*. 1992;15(4):777-790.
18. Ferrão YA, Miguel E, Stein DJ. Tourette's syndrome, trichotillomania, and obsessive-compulsive disorder: how closely are they related? *Psychiatry Res*. 2009;170(1):32-42.
19. Menzies L, Chamberlain SR, Laird AR, Thelen SM, Sahakian BJ, Bullmore ET. Integrating evidence from neuroimaging and neuropsychological studies of obsessive-compulsive disorder: the orbitofronto-striatal model revisited. *Neurosci Biobehav Rev*. 2008;32(3):525-549.
20. O'Sullivan RL, Rauch SL, Breiter HC, Grachev ID, Baer L, Kennedy DN, Keuthen NJ, Savage CR, Manzo PA, Caviness VS, Jenike MA. Reduced basal ganglia volumes in trichotillomania measured via morphometric magnetic resonance imaging. *Biol Psychiatry*. 1997;42(1):39-45.
21. Singer HS, Reiss AL, Brown JE, Aylward EH, Shih B, Chee E, Harris EL, Reader MJ, Chase GA, Bryan RN, et al. Volumetric MRI changes in basal ganglia of children with Tourette's syndrome. *Neurology*. 1993;43(5):950-956.
22. Stein DJ, Coetzer R, Lee M, Davids B, Bouwer C. Magnetic resonance brain imaging in women with obsessive-compulsive disorder and trichotillomania. *Psychiatry Res*. 1997;74(3):177-182.
23. Grachev ID. MRI-based morphometric topographic parcellation of human neocortex in trichotillomania. *Psychiatry Clin Neurosci*. 1997;51(5):315-321.
24. Keuthen NJ, Makris N, Schlerf JE, Martis B, Savage CR, McMullin K, Seidman LJ, Schmahmann JD, Kennedy DN, Hodge SM, Rauch SL. Evidence for reduced cerebellar volumes in trichotillomania. *Biol Psychiatry*. 2007;61(3):374-381.
25. Chamberlain SR, Menzies LA, Fineberg NA, Del Campo N, Suckling J, Craig K, Müller U, Robbins TW, Bullmore ET, Sahakian BJ. Grey matter abnormalities in trichotillomania: morphometric magnetic resonance imaging study. *Br J Psychiatry*. 2008;193(3):216-221.
26. Greer JM, Capecchi MR. *Hoxb8* is required for normal grooming behavior in mice. *Neuron*. 2002;33(1):23-34.
27. Garner JP, Weisker SM, Dufour B, Mench JA. Barbering (fur and whisker trimming) by laboratory mice as a model of human trichotillomania and obsessive-compulsive spectrum disorders. *Comp Med*. 2004;54(2):216-224.
28. Grant JE, Odlaug BL, Potenza MN. Addicted to hair pulling? how an alternate model of trichotillomania may improve treatment outcome. *Harv Rev Psychiatry*. 2007;15(2):80-85.
29. Novak CE, Keuthen NJ, Stewart SE, Pauls DL. A twin concordance study of trichotillomania. *Am J Med Genet B Neuropsychiatr Genet*. 2009;150B(7):944-949.
30. Gottesman II, Gould TD. The endophenotype concept in psychiatry: etymology and strategic intentions. *Am J Psychiatry*. 2003;160(4):636-645.
31. Le Bihan D, Mangin JF, Poupon C, Clark CA, Pappata S, Molko N, Chabriat H. Diffusion tensor imaging: concepts and applications. *J Magn Reson Imaging*. 2001;13(4):534-546.
32. Basser PJ, Mattiello J, LeBihan D. Estimation of the effective self-diffusion tensor from the NMR spin echo. *J Magn Reson B*. 1994;103(3):247-254.
33. Basser PJ, Pierpaoli C. Microstructural and physiological features of tissues elucidated by quantitative-diffusion-tensor MRI. *J Magn Reson B*. 1996;111(3):209-219.
34. Beaulieu C. The basis of anisotropic water diffusion in the nervous system: a technical review. *NMR Biomed*. 2002;15(7-8):435-455.
35. Suckling J, Davis MH, Ooi C, Wink AM, Fadiil J, Salvador R, Welchew D, Sendur L, Maxim V, Bullmore ET. Permutation testing of orthogonal factorial effects in a language-processing experiment using fMRI. *Hum Brain Mapp*. 2006;27(5):425-433.
36. Menzies L, Williams GB, Chamberlain SR, Ooi C, Fineberg N, Suckling J, Sahakian BJ, Robbins TW, Bullmore ET. White matter abnormalities in patients with

- obsessive-compulsive disorder and their first-degree relatives. *Am J Psychiatry*. 2008;165(10):1308-1315.
37. Suckling J, Bullmore E. Permutation tests for factorially designed neuroimaging experiments. *Hum Brain Mapp*. 2004;22(3):193-205.
 38. Bullmore ET, Suckling J, Overmeyer S, Rabe-Hesketh S, Taylor E, Brammer MJ. Global, voxel, and cluster tests, by theory and permutation, for a difference between two groups of structural MR images of the brain. *IEEE Trans Med Imaging*. 1999;18(1):32-42.
 39. Picard N, Strick PL. Motor areas of the medial wall: a review of their location and functional activation. *Cereb Cortex*. 1996;6(3):342-353.
 40. Rubia K, Russell T, Overmeyer S, Brammer MJ, Bullmore ET, Sharma T, Simmons A, Williams SC, Giampietro V, Andrew CM, Taylor E. Mapping motor inhibition: conjunctive brain activations across different versions of go/no-go and stop tasks. *Neuroimage*. 2001;13(2):250-261.
 41. Stein DJ, Chamberlain SR, Fineberg N. An A-B-C model of habit disorders: hair-pulling, skin-picking, and other stereotypic conditions. *CNS Spectr*. 2006;11(11):824-827.
 42. Stern E, Silbersweig DA, Chee KY, Holmes A, Robertson MM, Trimble M, Frith CD, Frackowiak RS, Dolan RJ. A functional neuroanatomy of tics in Tourette syndrome. *Arch Gen Psychiatry*. 2000;57(8):741-748.
 43. Sheehan DV, Lecrubier Y, Sheehan KH, Amorim P, Janavs J, Weiller E, Hergueta T, Baker R, Dunbar GC. The Mini-International Neuropsychiatric Interview (MINI): the development and validation of a structured diagnostic psychiatric interview for DSM-IV and ICD-10. *J Clin Psychiatry*. 1998;59(suppl 20):22-33.
 44. Nelson HE. *National Adult Reading Test (NART): Test Manual*. Windsor, England: NFER-Nelson; 1982.
 45. Montgomery SA, Asberg M. A new depression scale designed to be sensitive to change. *Br J Psychiatry*. 1979;134:382-389.
 46. Keuthen NJ, O'Sullivan RL, Ricciardi JN, Shera D, Savage CR, Borgmann AS, Jenike MA, Baer L. The Massachusetts General Hospital (MGH) Hairpulling Scale, 1: development and factor analyses. *Psychother Psychosom*. 1995;64(3-4):141-145.
 47. O'Sullivan RL, Keuthen NJ, Hayday CF, Ricciardi JN, Buttolph ML, Jenike MA, Baer L. The Massachusetts General Hospital (MGH) Hairpulling Scale, 2: reliability and validity. *Psychother Psychosom*. 1995;64(3-4):146-148.
 48. Smith SM, Jenkinson M, Woolrich MW, Beckmann CF, Behrens TE, Johansen-Berg H, Bannister PR, De Luca M, Drobnjak I, Flitney DE, Niazky RK, Saunders J, Vickers J, Zhang Y, De Stefano N, Brady JM, Matthews PM. Advances in functional and structural MR image analysis and implementation as FSL. *Neuroimage*. 2004;23(suppl 1):S208-S219.
 49. Chamberlain SR, Fineberg NA, Blackwell AD, Robbins TW, Sahakian BJ. Motor inhibition and cognitive flexibility in obsessive-compulsive disorder and trichotillomania. *Am J Psychiatry*. 2006;163(7):1282-1284.
 50. Bates JF, Goldman-Rakic PS. Prefrontal connections of medial motor areas in the rhesus monkey. *J Comp Neurol*. 1993;336(2):211-228.
 51. Luppino G, Matelli M, Camarda R, Rizzolatti G. Corticocortical connections of area F3 (SMA-proper) and area F6 (pre-SMA) in the macaque monkey. *J Comp Neurol*. 1993;338(1):114-140.
 52. Elliott R, Rubinsztein JS, Sahakian BJ, Dolan RJ. The neural basis of mood-congruent processing biases in depression. *Arch Gen Psychiatry*. 2002;59(7):597-604.
 53. Chambers CD, Bellgrove MA, Stokes MG, Henderson TR, Garavan H, Robertson IH, Morris AP, Mattingley JB. Executive "brake failure" following deactivation of human frontal lobe. *J Cogn Neurosci*. 2006;18(3):444-455.
 54. Chambers CD, Garavan H, Bellgrove MA. Insights into the neural basis of response inhibition from cognitive and clinical neuroscience. *Neurosci Biobehav Rev*. 2009;33(5):631-646.
 55. Rubia K, Smith AB, Brammer MJ, Taylor E. Right inferior prefrontal cortex mediates response inhibition while mesial prefrontal cortex is responsible for error detection. *Neuroimage*. 2003;20(1):351-358.
 56. Aron AR, Fletcher PC, Bullmore ET, Sahakian BJ, Robbins TW. Stop-signal inhibition disrupted by damage to right inferior frontal gyrus in humans. *Nat Neurosci*. 2003;6(2):115-116.
 57. Hampshire A, Chamberlain SR, Monti MM, Duncan J, Owen AM. The role of the right inferior frontal gyrus: inhibition and attentional control. *Neuroimage*. 2010;50(3):1313-1319.
 58. Stein DJ, Hollander E, Simeon D, Cohen L, Islam MN, Aronowitz B. Neurological soft signs in female trichotillomania patients, obsessive-compulsive disorder patients, and healthy control subjects. *J Neuropsychiatry Clin Neurosci*. 1994;6(2):184-187.
 59. Chamberlain SR, Fineberg NA, Blackwell AD, Clark L, Robbins TW, Sahakian BJ. A neuropsychological comparison of obsessive-compulsive disorder and trichotillomania. *Neuropsychologia*. 2007;45(4):654-662.
 60. Rosen HJ, Wilson MR, Schauer GF, Allison S, Gorno-Tempini ML, Pace-Savitsky C, Kramer JH, Levenson RW, Weiner M, Miller BL. Neuroanatomical correlates of impaired recognition of emotion in dementia. *Neuropsychologia*. 2006;44(3):365-373.
 61. Diefenbach GJ, Tolin DF, Meunier S, Worhunsky P. Emotion regulation and trichotillomania: a comparison of clinical and nonclinical hair pulling. *J Behav Ther Exp Psychiatry*. 2008;39(1):32-41.
 62. Christenson GA, Ristvedt SL, Mackenzie TB. Identification of trichotillomania cue profiles. *Behav Res Ther*. 1993;31(3):315-320.
 63. Diefenbach GJ, Mouton-Odum S, Stanley MA. Affective correlates of trichotillomania. *Behav Res Ther*. 2002;40(11):1305-1315.
 64. Flessner CA, Woods DW, Franklin ME, Keuthen NJ, Piacentini J. Cross-sectional study of women with trichotillomania: a preliminary examination of pulling styles, severity, phenomenology, and functional impact. *Child Psychiatry Hum Dev*. 2009;40(1):153-167.
 65. Drevets WC, Price JL, Simpson JR Jr, Todd RD, Reich T, Vannier M, Raichle ME. Subgenual prefrontal cortex abnormalities in mood disorders. *Nature*. 1997;386(6627):824-827.
 66. Johansen-Berg H, Gutman DA, Behrens TE, Matthews PM, Rushworth MF, Katz E, Lozano AM, Mayberg HS. Anatomical connectivity of the subgenual cingulate region targeted with deep brain stimulation for treatment-resistant depression. *Cereb Cortex*. 2008;18(6):1374-1383.
 67. Chamberlain SR, Menzies L. Endophenotypes of obsessive-compulsive disorder: rationale, evidence and future potential. *Expert Rev Neurother*. 2009;9(8):1133-1146.
 68. Grant JE, Correia S, Brennan-Krohn T. White matter integrity in kleptomania: a pilot study. *Psychiatry Res*. 2006;147(2-3):233-237.
 69. Szeszko PR, Ardekani BA, Ashtari M, Malhotra AK, Robinson DG, Bilder RM, Lim KO. White matter abnormalities in obsessive-compulsive disorder: a diffusion tensor imaging study. *Arch Gen Psychiatry*. 2005;62(7):782-790.
 70. Cannistraro PA, Makris N, Howard JD, Wedig MM, Hodge SM, Wilhelm S, Kennedy DN, Rauch SL. A diffusion tensor imaging study of white matter in obsessive-compulsive disorder. *Depress Anxiety*. 2007;24(6):440-446.
 71. Plessen KJ, Grüner R, Lundervold A, Hirsch JG, Xu D, Bansal R, Hammar A, Lundervold AJ, Wentzel-Larsen T, Lie SA, Gass A, Peterson BS, Hugdahl K. Reduced white matter connectivity in the corpus callosum of children with Tourette syndrome. *J Child Psychol Psychiatry*. 2006;47(10):1013-1022.
 72. Thomalla G, Siebner HR, Jonas M, Bäumer T, Biermann-Ruben K, Hummel F, Gerloff C, Müller-Vahl K, Schnitzler A, Orth M, Münchau A. Structural changes in the somatosensory system correlate with tic severity in Gilles de la Tourette syndrome. *Brain*. 2009;132(pt 3):765-777.