

### Vol No: 3, Issue: 1

Received Date: Jul 22, 2019  
Published Date: Aug 15, 2019

Anne Nora Heum Listerud

Sakina Tawakoli

Masoumah Soltani

Amila Topalovic

Unni Westerhagen

Torill Sauer\*

Department of Pathology, Akershus University  
Hospital, N-1478 Lorenskog, Norway

### Corresponding Author:

Torill Sauer\*

Department of Pathology, Akershus University Hospital  
and Institute of Clinical Medicine, Campus Ahus,  
University of Oslo, Sykehusveien, N-1478 Lorenskog,  
Norway.

## LBC versus Conventional Pap Smear in AGUS; Do we do any better with Liquid-Based Preparations?

### ABSTRACT

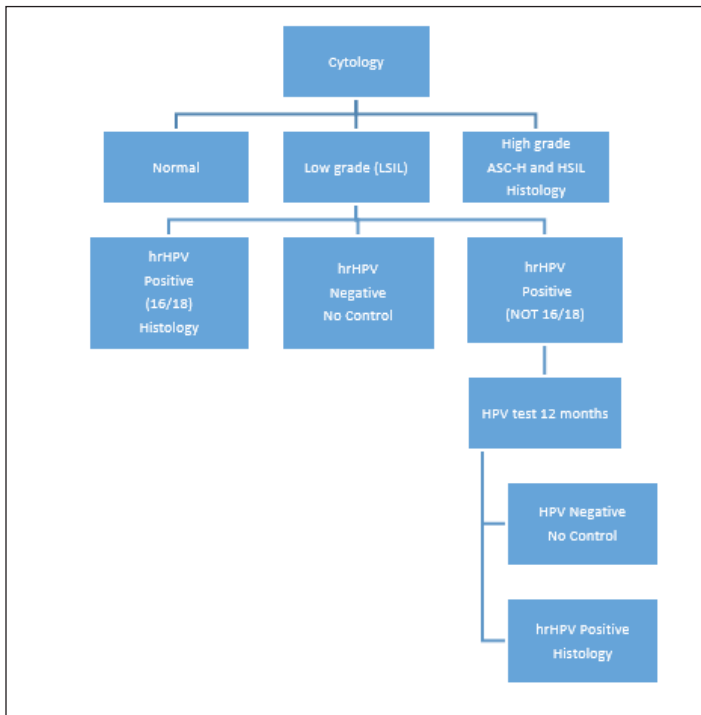
A diagnosis of AGUS is given when glandular cells of endocervical or endometrial origin (if > 45 of age) display nuclear atypia that exceeds obvious reactive changes but lack unequivocal features of adenocarcinoma in situ (ACIS) or invasive adenocarcinoma. The percentage of this diagnostic category varies considerably. The mean percentage of AGUS diagnoses in cervical cytology in Norway is 0.18% with a range of 0.06-0.48%. At Akershus University hospital (Ahus) 0.09% of cervical cytology diagnoses were AGUS in 2016. Our department changed from conventional to liquid-based slides during 2013-2014. The aim of our study was to see if the introduction of LBC had had any impact on the diagnosis of AGUS. We compared two cohorts of cervical smears: a three years cohort (2011-2013) of conventional Pap smears and a three years cohort (2014-2016) of Sure Path LBC smears. There were 82 women in the conventional Pap smear cohort (0.08%) and 95 in the Sure Path LBC cohort (0.09%) and all had histologic follow-up. There was no statistically difference in the results of the two cohorts. In conclusion, our major challenge in the diagnosis of AGUS are the cytological criteria and not our preparation method.

**Keywords:** Pap smear; AGUS, Adenocarcinoma in situ, HPV.

**Abbreviations:** AGUS: Atypical Glandular cells of Undetermined Significance; ACIS: Adenocarcinoma in situ; LBC: Liquid Based Cytology; LSIL: Low-grade Squamous Intraepithelial Lesion; HSIL: High-grade Squamous Intraepithelial Lesion; CIN: Cervical Intraepithelial Neoplasia; AGC: Atypical Glandular Cells; ICC: Immunocytochemistry; AGC NOS: Atypical Glandular Cells, not otherwise specified.

### INTRODUCTION

The Norwegian Cervical Cancer Screening Programme (NCCSP) started in 1995. The goal is to reduce incidence and mortality of cervical cancer in Norway [1]. The Bethesda classification system has been used since 2005 [2]. Women aged 25-69 are encouraged to participate triannually. An overview of the recommendations for squamous lesions is shown in **Figure 1**. Testing for high risk HPV types include 16, 18, 31, 33, 35, 39, 45, 51, 52, 54, 56, 58, 59, 66 and 68. Abnormal glandular findings (AGUS, ACIS and adenocarcinoma) always have histological work up [1]. The mean percentage of AGUS diagnoses in cervical cytology in Norway is < 0.2% [3] with a range of 0.06-0.48% between different pathology laboratories (mean 0.18%). At Akershus University hospital (Ahus) 0.09% (n = 31/34155) of cervical cytology diagnoses were AGUS in 2016.



**Figure 1:** Recommendations for follow-up of squamous cell abnormalities in the Norwegian Cervical Cancer Screening Programme.

A diagnosis of AGUS is given when glandular cells of endocervical or endometrial origin (if > 45 of age) display nuclear atypia that exceeds obvious reactive changes but lack unequivocal features of adenocarcinoma in situ (ACIS) or invasive adenocarcinoma [2]. The diagnostic criteria might be considered vague and not very specific. Consequently, the percentage of this diagnostic category varies considerably, and the results of histologic follow up likewise. The international literature gives percentages of AGUS in cervical cytology ranging from 0.047% to 0.6% [4-7]. The reproducibility of the diagnosis is reported ranging from poor to moderate [8, 9]. Follow-up histology is reported to be benign in > 50 % of cases in most studies [5,6,10,11].

Liquid-based preparations (LBC) were introduced in Norway with the introduction of HPV testing and practically all cytology laboratories now use either Thin Prep (Hologic) or Sure Path (BD) LBC for cervical cytology diagnostics. Our department changed from conventional to liquid-based slides during 2013-2014. The aim of our study was to see if the introduction of LBC had had any impact on the diagnosis of AGUS. We wanted to compare two cohorts of cervical smears: a three years cohort (2011-2013) of conventional Pap smears and a three years cohort (2014-2016) of Sure Path smears.

## MATERIAL AND METHODS

Women with a cytological diagnosis of AGUS in the department's computer system (Doculive Patologi) were identified according to topography/preparation code (conventional or LBC) and the morphology code for AGUS (M81401). There were 82 women in the conventional Pap smear cohort (2011-2013) ( $82/91983 = 0.08\%$ ) and 95 in the Sure Path LBC cohort (2014-2016) ( $95/99525 = 0.09\%$ ). Some had more than one cervical smear and the total number of smears was 214. Histological follow up had been done on all women within one year. The histological diagnoses were grouped as benign, premalignant and malignant. One biopsy with a non-specific diagnosis and two cases without representative tissue material were grouped together. As for AGUS cases, the first period represents cases diagnosed on conventional Pap smears and the latter on LBC slides. The percentages of cytological ACIS diagnoses in the two periods was calculated from the database for comparison, but ACIS was not within the scope of this study and thus not further examined.

For statistical calculations premalignant and malignant were grouped together. The benign and the "no diagnosis" categories were likewise grouped together as benign. *Chi-square test* with *p-value* was calculated for possible significant diagnostic differences between Pap smear and LBC preparations.

## RESULTS

An overview of the diagnoses is given in **Tables 1 & 2**. *Chi-square test* did not show any significant differences between the two preparations methods. *P-value* for findings in the cervix in Pap smears versus LBC smears was 0.06 and for endometrial findings 0.88. Thus, there was no significant difference in premalignant/malignant findings in the cervix or the endometrium in Pap smears versus LBC slides. Histological diagnoses in cervical lesions were benign in 48% (38/78) of Pap smears and in 61% (38/78) in LBC slides. Histological follow up for endometrial lesions were benign in 61% and 65%, respectively, for Pap smears and LBC slides. The percentage of cells (thought to be) of endometrial origin was larger in LBC slides than in Pap smears 39% (46/118) versus 19% (18/96).

The percentages of ACIS were 0.02% ( $n = 23$ ) (2011-2013) and 0.036% ( $n = 36$ ) (2014-2016), respectively, all but one with histological correlation. In the Pap smear cohort 22/23 were confirmed to be ACIS whereas 1 case was squamous CIN 3. In

the LBC cohort there were 6/36 squamous CIN 3, 28/36 ACIS, 1 endometriosis (false positive) and 1 without follow up.

**Table 1:** Overview of cyto-histological correlation according to number of smears.

Preparation method	Diagnostic Category	Cervix	Endometrium
Pap smear	Benign (n = 43)	34	9
	Premalignant (n = 36)	36	0
	Malignant (n = 11)	4	7
	No diagnosis (n = 6)	4	2
Subtotals = number of Pap smears	96	78 (81%)	18 (19%)
Sure Path LBC	Benign (n = 70)	44	26
	Premalignant (n = 29)	23	6
	Malignant (n = 15)	5	10
	No diagnosis (n = 4)	0	4
Subtotals = number of LBC smears	118	72 (61%)	46 (39%)

According to **Table 2** this would apply to both benign and malignant lesions.

**Table 2:** Histological findings in all AGUS cases.

Histological diagnosis	Pap cervix	LBC cervix	Pap endometrium	LBC endometrium
No diagnosis	2		3	2
Normal	23	36		4
Benign NOS#	11	8	8	23
AGUS (irregular endocervical cells = M81401)	2	2		
ACIS	18	9	1*	7*
Adenocarcinoma	4	5	6	10
LSIL	4	1		
HSIL	14	11		

\*AGUS cells presumed to be of endometrial origin, but turned out to be endocervical ACIS.

# including polyps, cilia and squamous metaplasia, inflammatory and hormonal changes.

## DISCUSSION

LBC preparations have a superior morphology over Pap smears. In conventional Pap smears, we often struggled with technical artefacts as to smearing technique and suboptimal fixation as well as obscuring amounts of blood, granulocytes, debris and mucus. Despite that, our AGUS results show that we do not do significantly better with LBC slides. These findings

are in accordance with Wang et al. [12].

As in the literature [5,6,10,11], the majority of our cases were histologically benign, and there was no significant difference between the two periods. We seem to see more endometrial cells, but the majority are benign on follow-up, and the differences are not significant. Could we have improved in other ways? The percentage of ACIS increased from the first to the second period, suggesting that we gave more specific diagnoses after converting to LBC. The absolute numbers were low, and random variations must be taken into consideration.

Other studies have found that subcategorization of AGUS may give a higher yield of significant lesions in specific subgroups [11,13-15], namely AGC (atypical glandular cells) favor neoplastic versus AGC NOS. Recommendations in Norway do not include this subcategorization and is not routine in most national laboratories. Lee et al. [13] demonstrated increased use of AGC favor atypical endocervical cells versus AGC NOS in LBC slides.

Our LBC material enable the investigation of adjunct analyses as HPV and immunocytochemistry (ICC) for selected markers, but none are in routine use or as general recommendations. Detection of high risk HPV [16] would underscore the need for histological work up, but a negative HPV would not obviate it. The same applies to ICC markers. Risse et al. [17] found that the additional use of cell blocks increased the yield of significant lesions to 61.5%, due to detecting benign columnar lesion mimics which might have obviated histological work up in such cases.

Our material does not allow us to assess the long time risk of malignancy. Wang et al. [7] found a high and persistent risk of cervical cancer (especially cervical adenocarcinoma) for up to 15 years in a Swedish study. The demographics of the populations in Norway and Sweden are quite similar. We can assume that the risk of an underlying malignant or premalignant lesion is of the same magnitude in Norway, and our current practice of follow up is justified and in compliance with international studies [10,13,15].

## CONCLUSION

In conclusion, our major challenge in the diagnosis of AGUS are the cytological criteria and not our preparation method. The enhanced morphology may allow us to diagnose more cases accurately as ACIS, but within the AGUS category the morphological abnormalities are often discrete and there is

overlap of criteria of a number of benign columnar lesions and malignant or premalignant ones.

## REFERENCES

1. Registry TNC. (2017). The Norwegian Cervical Cancer Screening Programme (NCCSP).
2. Covell JL, Wilbur DC, Guidos B, Lee KR, Chieng DC, Mody DR. (2004). *Epithelial Abnormalities: Glandular*, Springer, New York, USA.
3. Registry TNC. (2016). Annual Report 2016 Cervical Screening Programme.
4. Kim MK, Lee YK, Hong SR and Lim KT. (2017). Clinicopathological significance of atypical glandular cells on cervicovaginal Pap smears. *Diagn Cytopathol.* 45(10): 867-872.
5. Pradhan D OR, Patadji S, Zhao C. (2016). Clinical Significance of Atypical Glandular Cells in Pap Tests: An Analysis of More Than 3000 Cases at a Large Academic Women's Center. *Cancer Cytopathol.* 124(8): 589-595.
6. Toyoda S, Kawaguchi R, Kobayashi H. (2019). Clinicopathological Characteristics of Atypical Glandular Cells Determined by Cervical Cytology in Japan: Survey of Gynecologic Oncology Data from the Obstetrical Gynecological Society of Kinki District, Japan. *Acta Cytol.* 2: 1-10.
7. Wang J, Andrae B, Sundstrom K, Strom P, et al. (2016). Risk of invasive cervical cancer after atypical glandular cells in cervical screening: nationwide cohort study. *BMJ.* 352: i276.
8. Lepe M EC, Quddus MR, Paquette C. (2018). Atypical Glandular Cells: Interobserver Variability according to Clinical Management. *Acta Cytol.* 62(5-6): 397-404.
9. Simsir A, Hwang S, Cangiarella J, Elgert P, et al. (2003). Glandular cell atypia on Papanicolaou smears: interobserver variability in the diagnosis and prediction of cell of origin. *Cancer.* 99(6): 323-330.
10. Shoji T, Takatori E, Takeuchi S, Yoshizaki A, et al. (2014). Clinical significance of atypical glandular cells in the Bethesda system 2001: a comparison with the histopathological diagnosis of surgically resected specimens. *Cancer Invest.* 32(4): 105-109.
11. Tam KF, Cheung AN, Liu KL, Ng TY, et al. (2003) A retrospective review on atypical glandular cells of undetermined significance (AGUS) using the Bethesda 2001 classification. *Gynecol Oncol.* 91(3): 603-607.
12. Wang N, Emancipator SN, Rose P, Rodriguez M, et al. (2002). Histologic follow-up of atypical endocervical cells. *Acta Cytol.* 46(3): 453-457.
13. Lee CY and Ng WK. (2008) Follow-up Study of Atypical Glandular Cells in Gynecologic Cytology Using Conventional Pap Smears and Liquid-Based Preparations: Impact of the Bethesda System 2001. *Acta Cytol.* 52(2): 159-168.
14. Reynolds JP, Salih ZT, Smith AL, Dairi M, et al. (2018). Cytologic parameters predicting neoplasia in Papanicolaou smears with atypical glandular cells and histologic follow-up: a single-institution experience. *J Am Soc Cytopathol.* 7(1): 7-15.
15. Boyraz G, Basaran D, Salman MC, Ibrahimov A, et al. (2017). Histological Follow-Up in Patients with Atypical Glandular Cells on Pap Smears. *J Cytol.* 34(4): 203-207.
16. Zhao C, Florea A and Austin RM. (2010). Clinical utility of adjunctive high-risk human papillomavirus DNA testing in women with Papanicolaou test findings of atypical glandular cells. *Arch Pathol Lab Med.* 134(1): 103-108.
17. Risse EK, Holierhoek JP, Meijer-Marres EM, Ouwkerker-Noordam E, et al. (2011). Increased diagnostic accuracy of atypical glandular cells in cervical liquid-based cytology using cell blocks. *Cytopathology.* 22(4): 253-260.

**Copyright:** Sauer T, et al. © 2019. This is an open-access article distributed under the terms of the Creative Commons Attribution License, which permits unrestricted use, distribution, and reproduction in any medium, provided the original author and source are credited.